

Challenging Infectious Disease Cases

James H. Maguire, MD
Senior Physician

Division of infectious Disease and Department of Medicine
Brigham and Women's Hospital
Professor of Medicine
Harvard Medical School

**CONTINUING MEDICAL EDUCATION
DEPARTMENT OF MEDICINE**



**HARVARD MEDICAL SCHOOL
TEACHING HOSPITAL**

James H. Maguire, MD



- Harvard Medical School
- Internal Medicine Residency and Infectious Disease Fellowship, Peter Bent Brigham Hospital
- Professor of Medicine, Harvard Medical School; Senior Physician, Brigham and Women's Hospital
 - Focus: parasitic disease, musculoskeletal infections

Disclosures

- I have no financial disclosures

Objectives

Through discussion of challenging clinical cases:

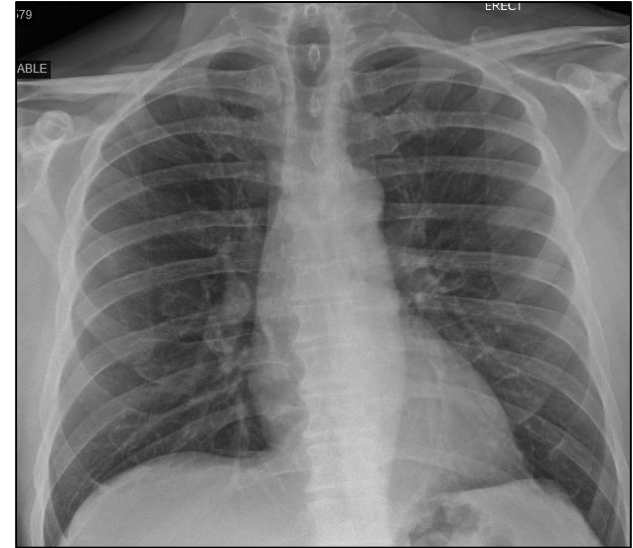- Expand differential diagnosis of infectious diseases
- Discuss strategies for diagnosis and management of important infectious diseases and syndromes

Case 1:

72-year-old man with fever, headache, loose stool

- History of hypertension, otherwise healthy
- Spring 2020: traveled to large city in NY, spent 3 hours with relative who died from COVID-19; used mask
- 5 days later: sudden onset of fever, headache, loose stool, cough, no SOB
- Primary care physician arranged nasopharyngeal swab for COVID; home oximeter
- O₂ sat 94%; home oxygen, acetaminophen
- Following day: still febrile, headache, slight cough, absolute lymphocyte count 120; temperature 104° F, sent to ER

- Emergency room: ill appearing, temperature 103° F, O₂ sat 96% on room air, lungs clear
- WBC 4530, lymphocytes 180, platelets 63,000, PT/PTT normal,
- AST 174, ALT 190
- LDH 699, CRP 289; D-Dimer >4000, Ferritin 19,100; Procalcitonin 1.62
- CXR clear
- Admit to SPU (Special Pathogens Unit): probable COVID-19

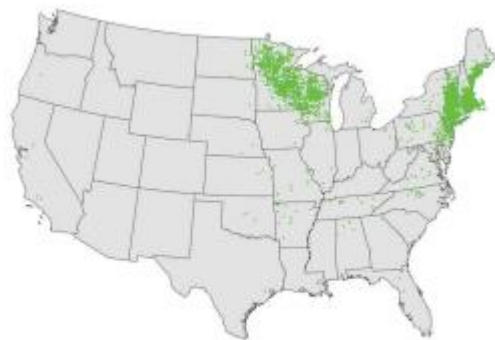

Other studies?


- Blood cultures negative; chest CT: no opacities
- Further questioning: removed tick from arm 10 days earlier
- Peripheral blood smear: low platelets, 7% atypical lymphocytes, no intracellular parasites/inclusions
- Given doxycycline 100 mg PO q12h
- Defervesced overnight, felt better
- NP swab for SARS-CoV2 (-) x3
- Clinical diagnosis: **anaplasmosis**
- Studies for tick-borne disease:
 - Lyme serology (-),
 - PCR for Babesia (-),
 - Anaplasma phagocytophilum* PCR (+)
- Doxycycline x 10 days, full recovery

Human granulocytic anaplasmosis

- Rickettsia-like bacterial infection; in US transmitted by *Ixodes scapularis* and *pacificus*



ANAPLASMOSIS



Ixodes scapularis

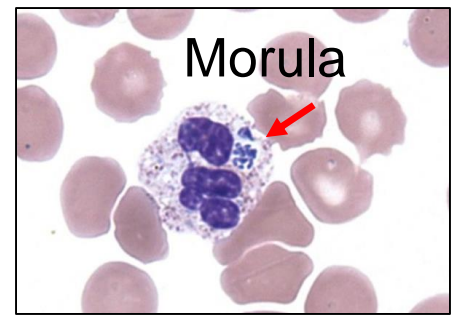
Table 1

Published signs, symptoms, and key laboratory abnormalities (%) reported among laboratory-confirmed HGA in the USA, Europe, and in Asia (N = 68 to 794 across features)

Frequency of Complaint	Symptom, Sign, or Laboratory Abnormality (Number of Patients Evaluated)	Median % (IQR)
Common	Fever (794)	100 (90–100)
	Malaise (391)	97 (90–98)
	Headache (648)	82 (64–93)
	Myalgia (789)	76 (67–87)
	Arthralgia (661)	56 (27–69)
	Increased serum ALT or AST level (397)	83 (63–98)
	Thrombocytopenia (566)	75 (61–91)
	Leukopenia (566)	55 (47–71)
Less common	Stiff neck (64)	45 (34–48)
	Nausea (521)	39 (35–49)
	Cough (523)	29 (20–30)
	Increased serum creatinine level (199)	49 (25–71)
	Anemia (198)	28 (6–44)
Uncommon	Diarrhea (317)	21 (13–28)
	Vomiting (312)	20 (19–29)
	Confusion (470)	17 (17–18)
	Rash ^a (489)	6 (3–10)

Infect Dis Clin N Am 29 (2015) 341–355

Anaplasmosis

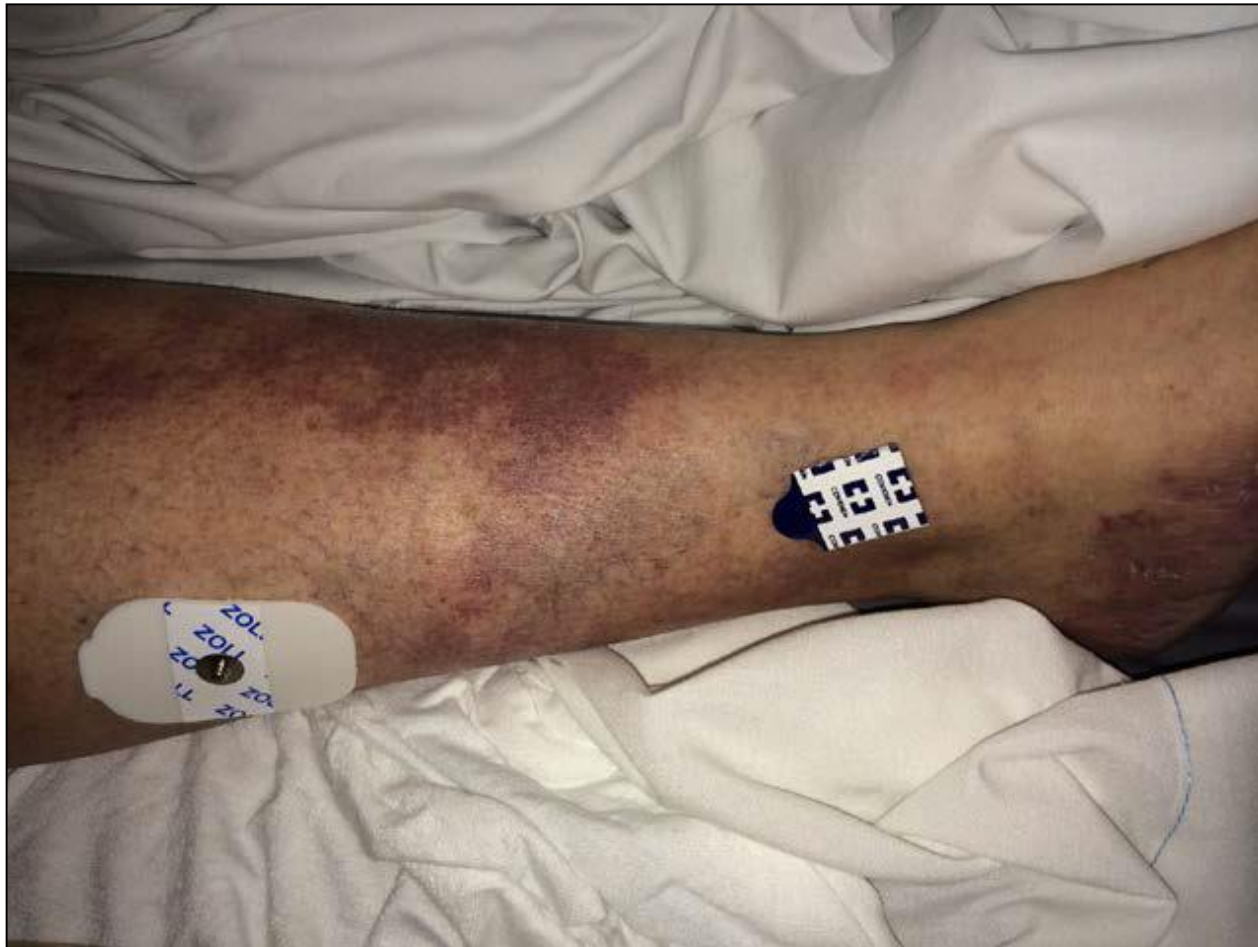

- Diagnosis
 - Clinical
 - Morulae in neutrophils (insensitive)
 - Confirm with PCR-based assay, serology (4-fold rise in IgG antibodies)
- Treatment
 - Doxycycline x 10-14 days (all ages)
 - Alternative rifampin (pregnancy)
 - Empirical treatment before results of diagnostic tests become available can be lifesaving in cases of potentially rapidly progressive tick-borne diseases with nonspecific presentations (e.g, RMSF, anaplasmosis)

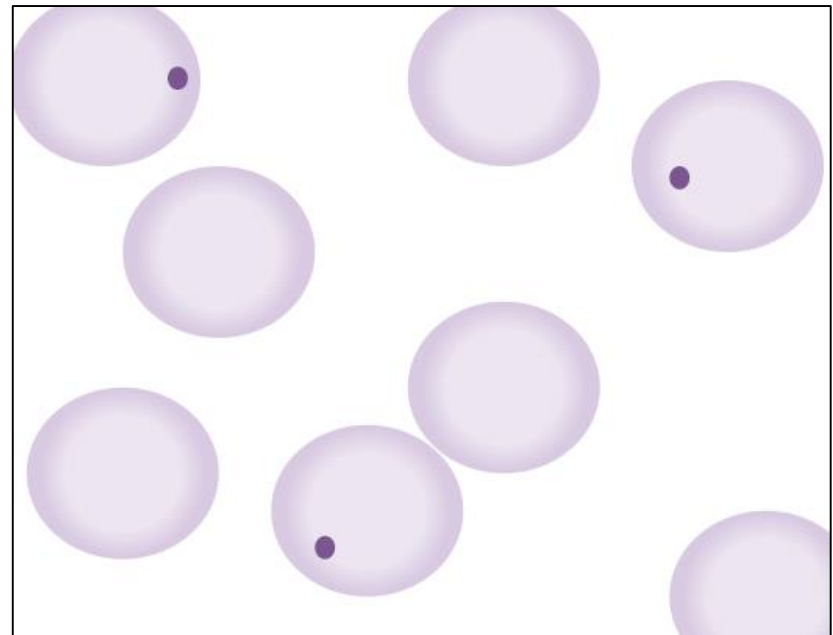
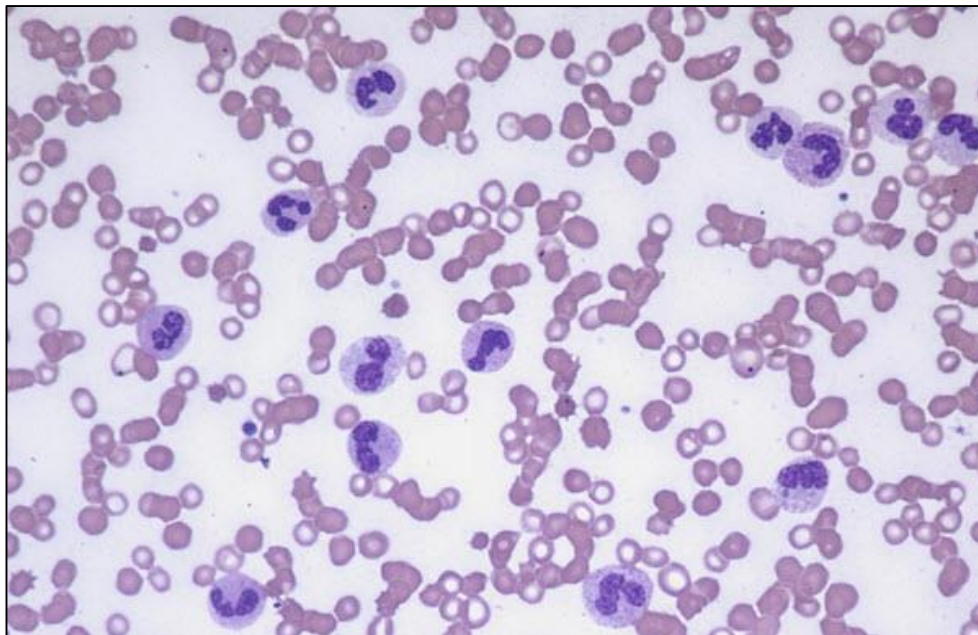
Case 2: 49-year-old woman with fever, hypotension, WBC 77,000

- 1 day before admission sudden onset of rigors, vomiting, and weakness
- Noticed red, purple lesions on both lower legs
- Told she had acute leukemia; blood cultures were obtained
- Vancomycin and piperacillin/tazobactam administered, and transferred to BWH

- On admission: temperature 101.6°F: she was hypotensive with cyanosis of the lips, dusky digits, purpuric and petechial lesions on legs
- Pressors started



- WBC 79,000 with 24% bands, hematocrit 41, platelets 116,000
- Creatinine 0.9, ALT 243, AST 344, alkaline phosphatase 86
- Blood smear: Immature forms but no blasts; toxic granulations, Howell-Jolly bodies



- Lives in suburbs of Boston, no recent travel, has a pet dog

Diagnosis?

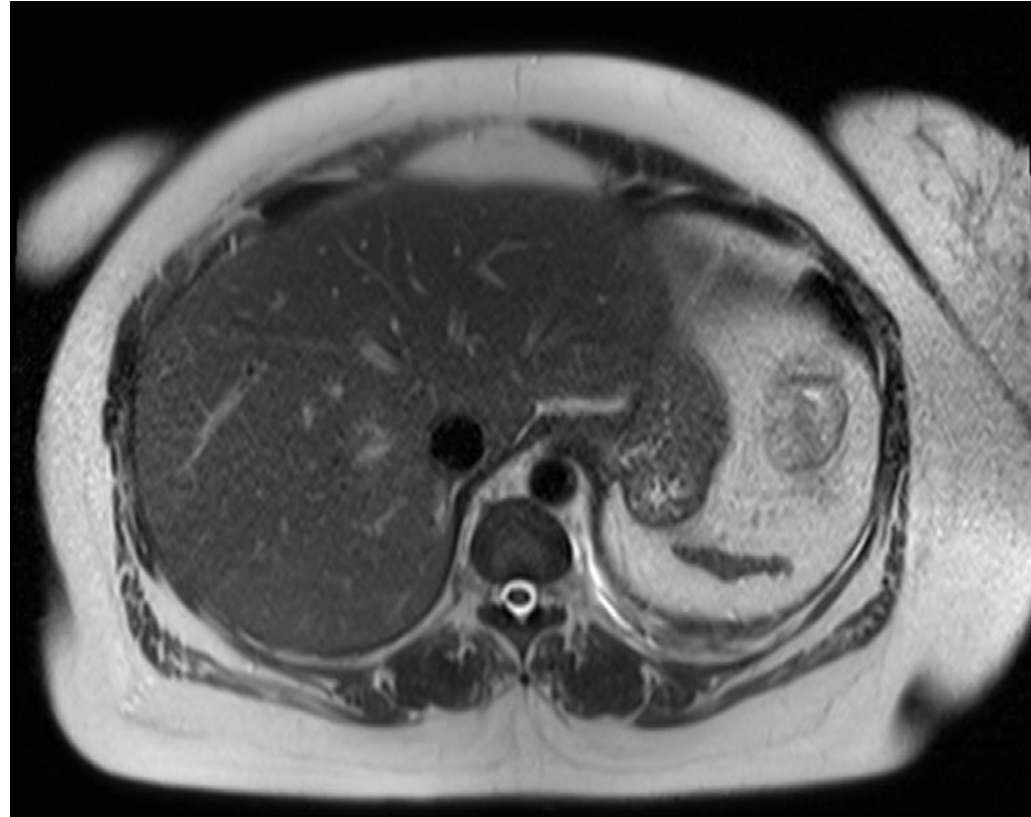
Management?

- Lives in suburbs of Boston, no recent travel, has a pet dog

Diagnosis?

Management?

CT scan of the abdomen: Atrophic spleen

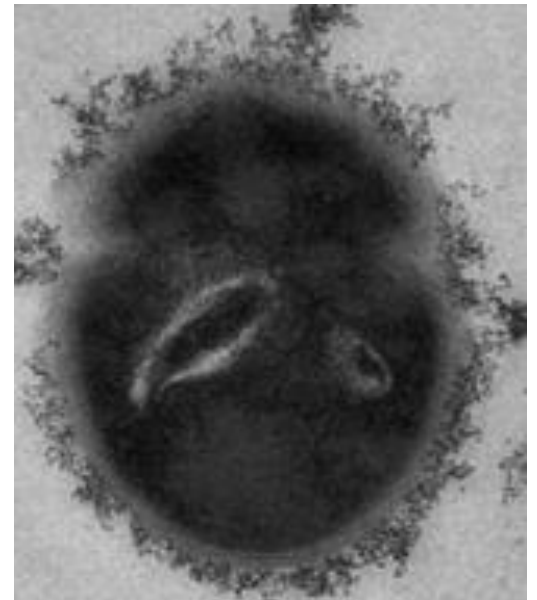
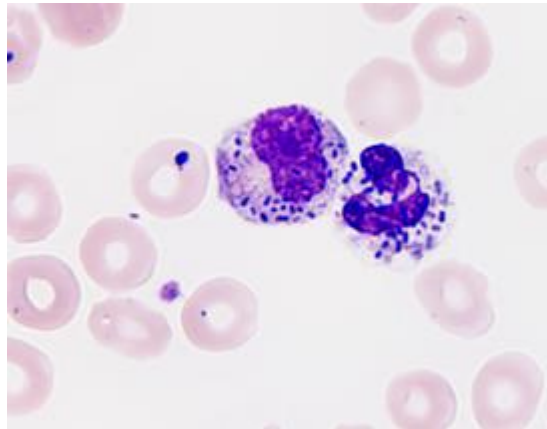
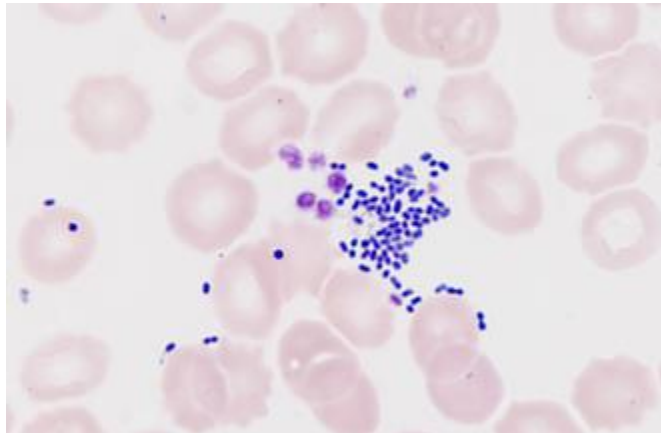


Blood cultures: gram-positive cocci in pairs

Overwhelming sepsis and asplenia

- Encapsulated bacteria:
 - *Streptococcus pneumoniae* (50-90%)
 - *Haemophilus influenzae*
 - *Neisseria meningitidis*
 - *Capnocytophaga canimorsus*
- Rare cases of other bacteria
- Intracellular organisms:
 - Babesia
 - Malaria

- Our patient: *Streptococcus gallolyticus* ssp. *pasteurianus*
- Formerly *Streptococcus bovis* (group D streptococcus)
 - Subtype I *Streptococcus gallolyticus*
 - Subtype II/1 *Streptococcus infantarius*
 - Subtype II/2 *Streptococcus pasteurianus*
- Rx: intravenous ceftriaxone
- Echocardiogram and colonoscopy: normal
- (*S. gallolyticus* associated with colonic carcinoma, endocarditis)



Advice for asplenic patients

- Vaccinations, antibiotics
- Medical alert
- Safe animal handling
- Travel to remote areas
- Travel to malaria-endemic areas
- Exposure to tick-infested areas
- Information sheet for patients

Case 3: 22-year-old woman: acute onset of fever, pain, swelling in right knee

- Excellent health, no medications
- Intravenous drug use; sexually active with new partner
- Exam: 100.1°F, right knee swollen with effusion, warm, tender, range of motion limited by pain
- Two small pustular lesions on her left foot
- WBC, 14,500; CRP 42; synovial fluid WBC: 73,000, 93% PMNS; smear negative

22 year old woman with new sexual partner and recent IV drug use and suspected acute septic arthritis

Which of the following is the most appropriate regimen while awaiting culture results?

- A. Vancomycin
- B. Ceftriaxone
- C. Vancomycin and ceftriaxone
- D. Ceftriaxone and metronidazole
- E. Vancomycin, ceftriaxone, and metronidazole

22-year-old woman with new sexual partner and recent IV drug use and suspected acute septic arthritis

Which of the following is the most appropriate regimen while awaiting culture results?

- A. Vancomycin
- B. Ceftriaxone
- C. Vancomycin and ceftriaxone
- D. Ceftriaxone and metronidazole
- E. Vancomycin, ceftriaxone, and metronidazole

She is at high risk of *S. aureus* infection because of her IV drug use and gonococcal infection because of her sexual contact; anaerobes such as *B. fragilis* would be an extremely unusual causes of acute septic arthritis. Empirical coverage for *Pseudomonas* (e.g., cefepime) could be considered because of her intravenous drug use.

Case history

- Vancomycin started; arthroscopic lavage of the knee
- Post-operative day 2:
 - Synovial fluid cultures: gram-negative diplococci
 - Blood cultures: negative
 - Cervical, urethral, rectal, pharyngeal cultures: negative for gonococci
- Vancomycin stopped, ceftriaxone started
- Cultures: *Neisseria meningitidis*
- 2 weeks ceftriaxone → full recovery

Disseminated gonococcal infection

- Occurs in 0.5-3% of patients with *N. gonorrhoeae* infection
- Venereal infection (anogenital region, pharynx) usually asymptomatic,
- Two syndromes
 - Tenosynovitis, dermatitis, and polyarthralgia without purulent arthritis (bacteremic phase)
 - Purulent arthritis
- Treatment:
 - Purulent arthritis: 7-14 days of antibiotics (daily ceftriaxone), drainage of joint
 - Otherwise, 7 days, can complete therapy with oral agent if sensitive (e.g., cefixime)
 - Doxycycline not azithromycin for chlamydia
 - Test for syphilis, HIV
- Meningococcemia can present similarly!

Case 4: 67-year-old man with prolonged fever

- In excellent health, felt sluggish x several days
- Sudden onset: chills, anorexia, fatigue, myalgia
- Two days later: fever to 102-103°, drenching sweats
- WBC 4300, 58% PMNs, 22% lymphocytes, 17% monocytes, ESR 16, negative antibody test for Lyme disease, negative blood cultures
- CXR, CT unremarkable
- No improvement with empirical course of moxifloxacin

- PMH-unremarkable. Works as attorney, lives in NH, has grown children, no pets, traveled years ago to Europe
- Admitted after 3 weeks of fever
- Examination: T102°F, fatigued, no acute distress. Mild scleral icterus. Lungs clear. No murmurs. No adenopathy. Liver edge palpable, not tender. No edema. No rash.
- WBC 11,500; 30N, 59L, 9Mo, Hct 40.8, plts 200,000, ESR 42, creatinine 1.1, ALT 117, AST 107, alk phos 643, GGT 1122, LDH 457, bili 4.2/5.5

Differential diagnosis? Studies?

- Admitted for work-up of fever
- U/S: enlarged spleen, normal bile ducts
- Smear: atypical lymphocytes
- CMV and toxoplasma IgG and IgM, HIV: negative
- Heterophile: positive
- EBV anti VCA-IgM >1:40; IgG 1:1240
- Contact with 18-month-old granddaughter who attended day care
- Prolonged convalescence

**Diagnosis: infectious mononucleosis with
cholestatic hepatitis**

Acute EBV infection in older adults

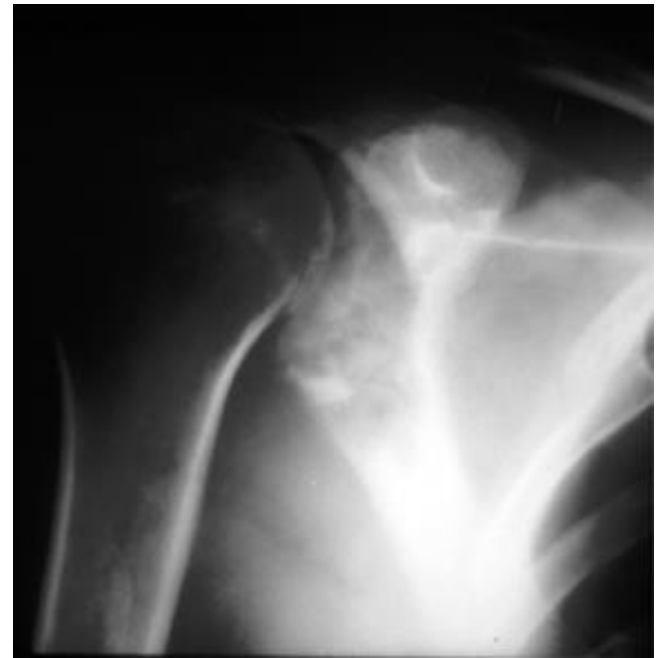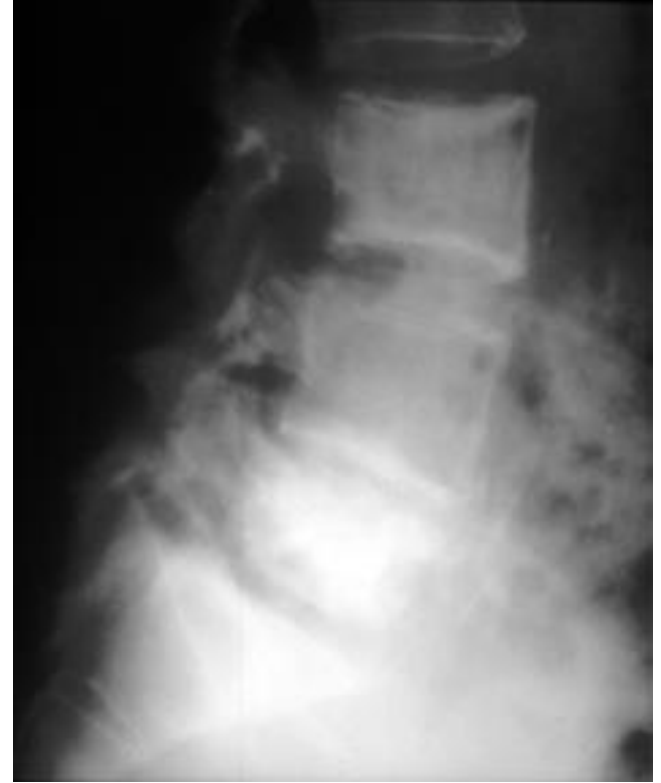
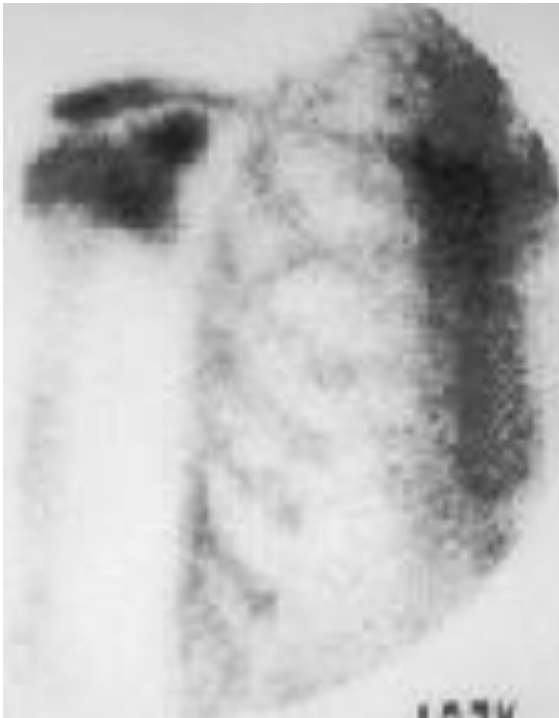- 90% adults >40yrs infected earlier in life
- Illness more severe than in younger persons
- Less common: pharyngitis, lymphadenopathy, splenomegaly, lymphocytosis
- More common: prolonged fever, liver involvement, jaundice

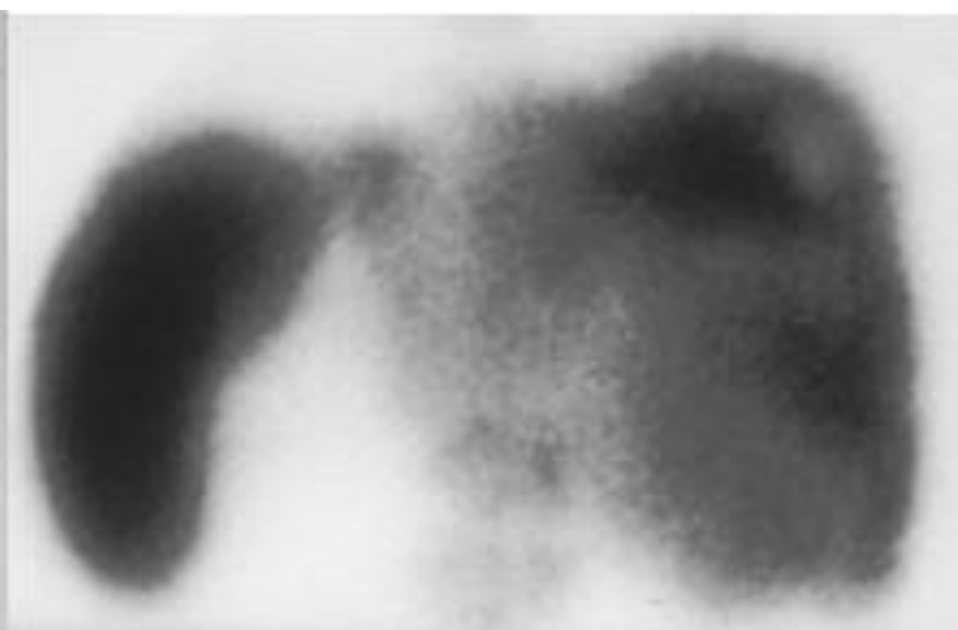
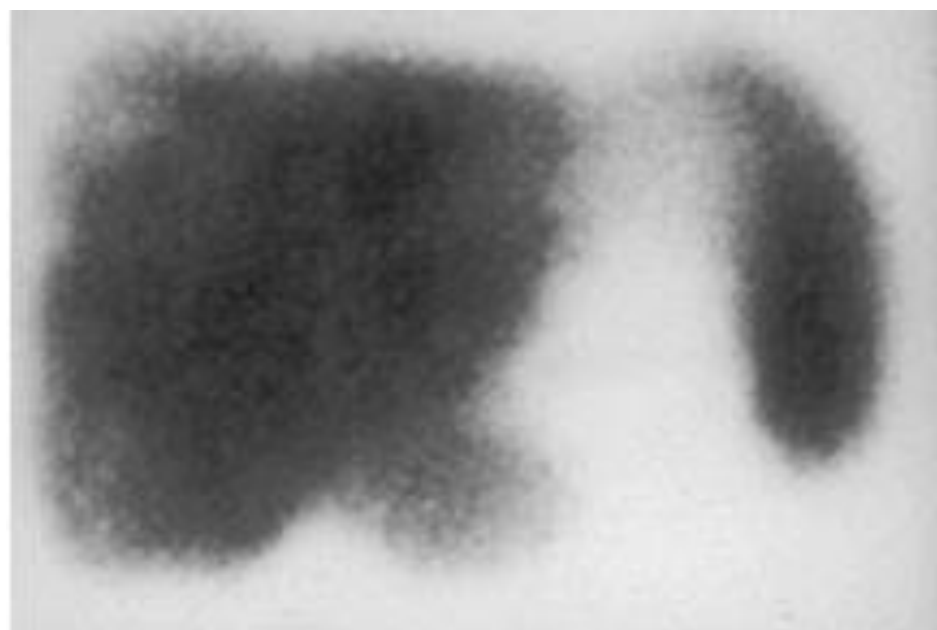
Case 5: 39-year-old veteran with 8-month history of back pain and 20-lb weight loss

- Pain was constant, did not increase with coughing or movement
- No fever, sweats, anorexia, cough, abdominal pain, diarrhea or constipation
- No history of trauma
- Past medical history unremarkable; served in Vietnam during war; travel to Korea

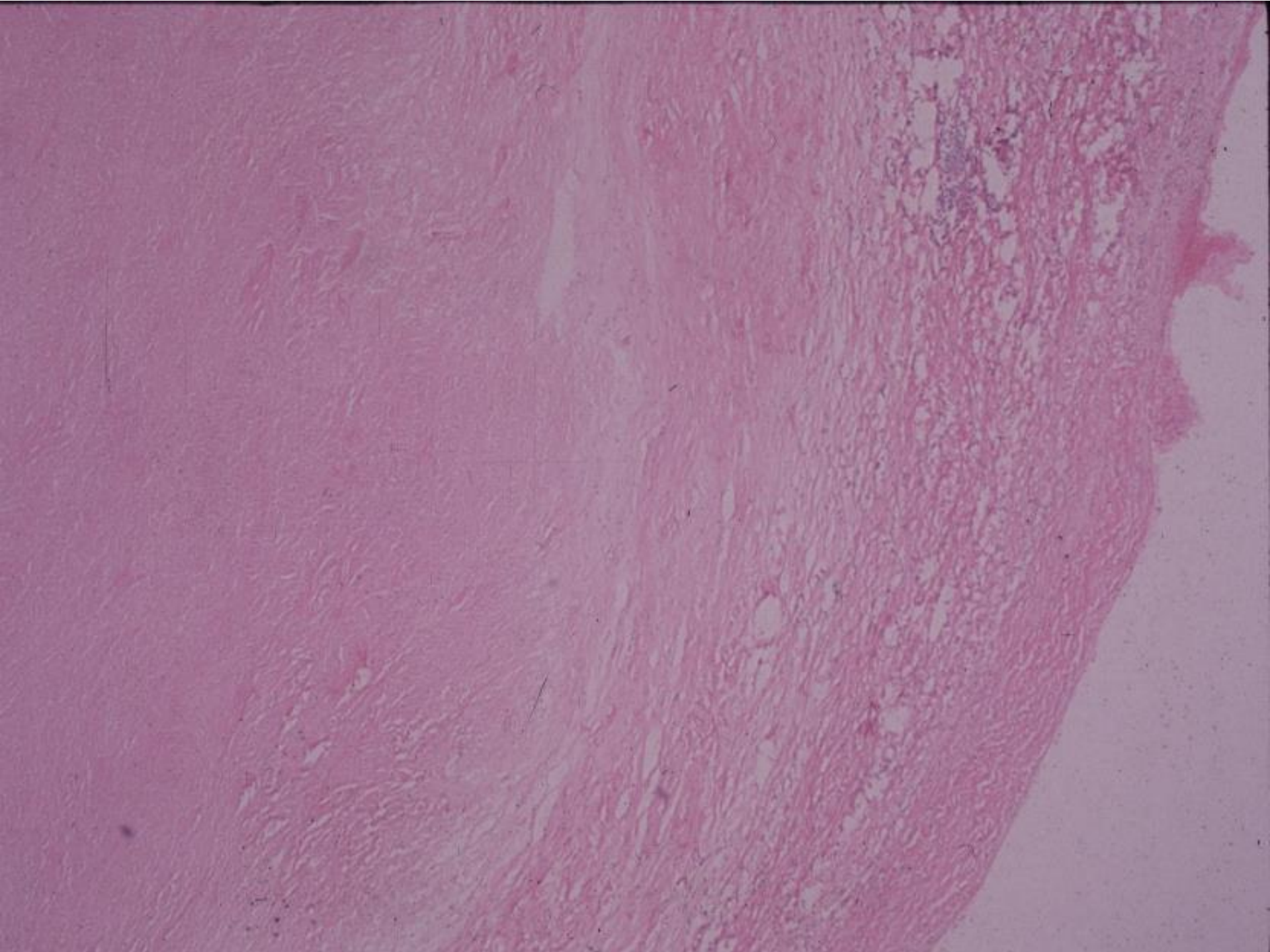
- Physical examination: afebrile, low back tenderness, enlarged liver and spleen, both extending several centimeters below costal margin
- Hematocrit 36%, WBC 8700 (69 polys, 6 bands, 8 lymphs, 13 monos, 4 eos), ESR 122, alkaline phosphatase 199 (normal 30-115), other liver function tests normal
- Tuberculin skin test: positive at 20mm of induration

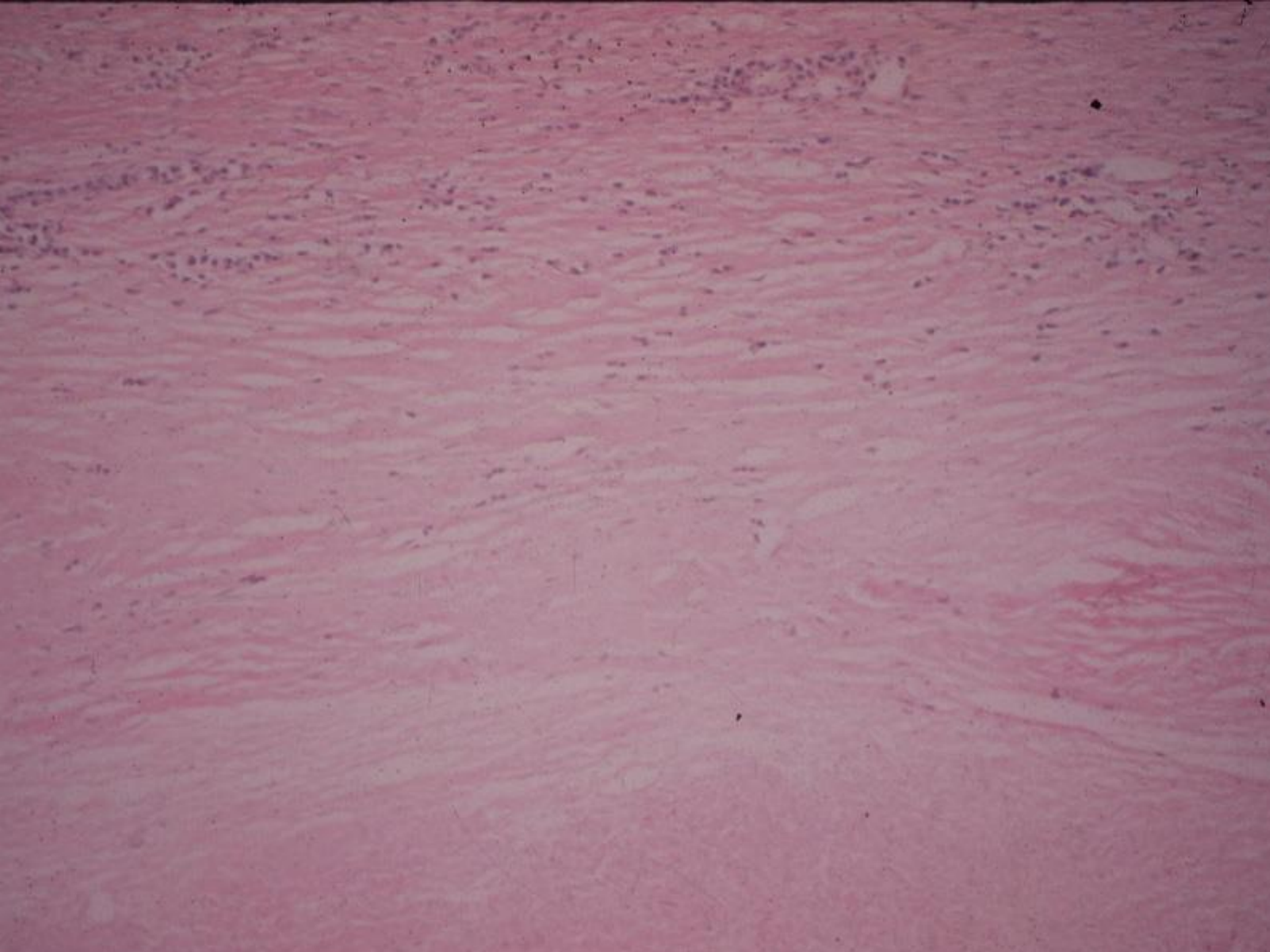
- X-rays: sclerotic/lytic lesions in several vertebrae, right scapula, elsewhere
- Ultrasound, gallium scan, and CT scan of the liver: several large hypodense lesions

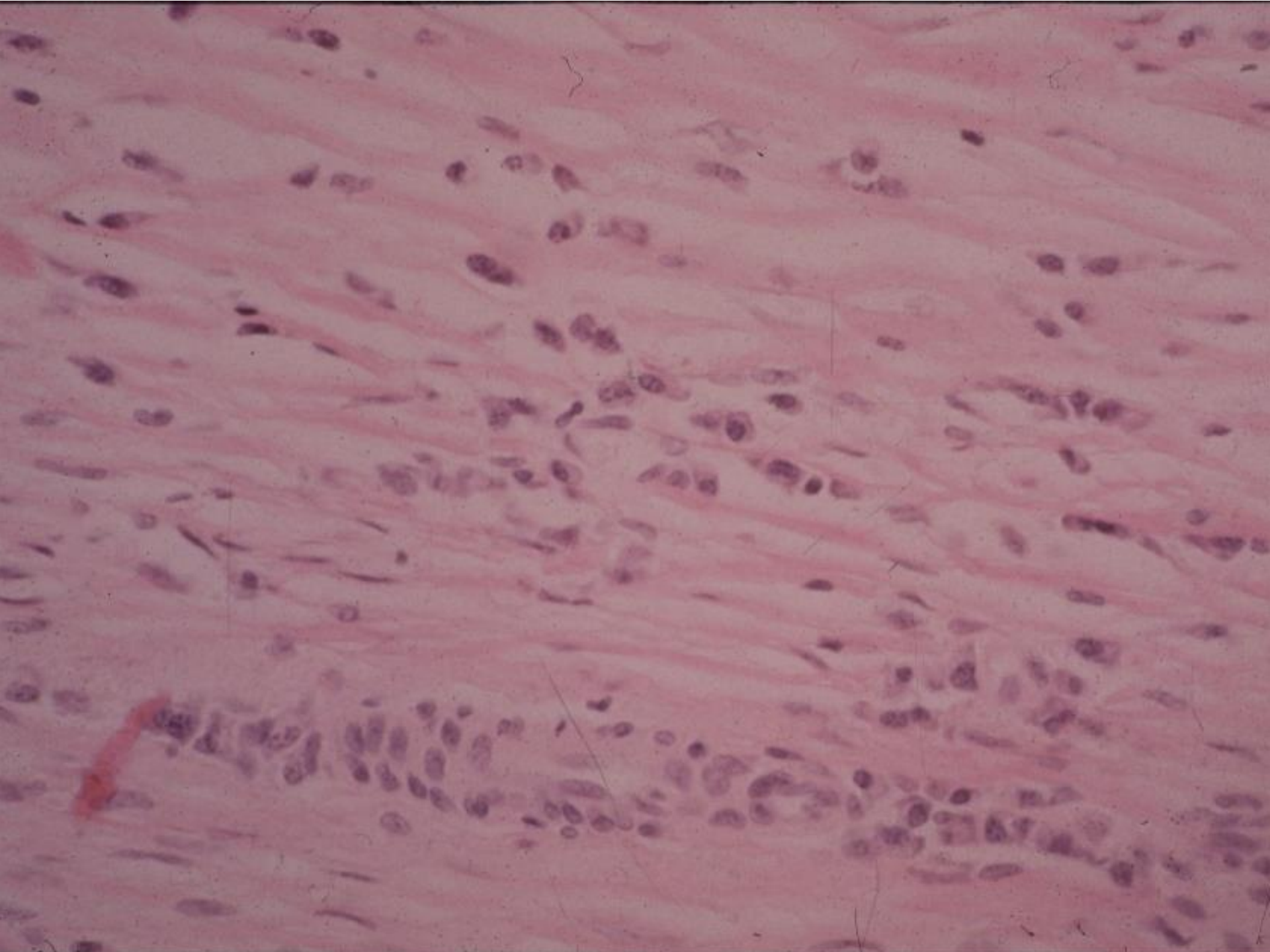




- Bone marrow biopsy and 2 needle biopsies of the liver non-diagnostic
- Open liver biopsy: large area of necrosis, surrounded by epithelioid cells, a few giant cells, infiltrates of plasma cells and lymphocytes, and dense fibrous tissue



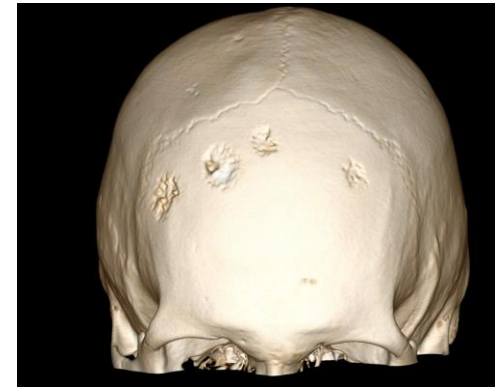
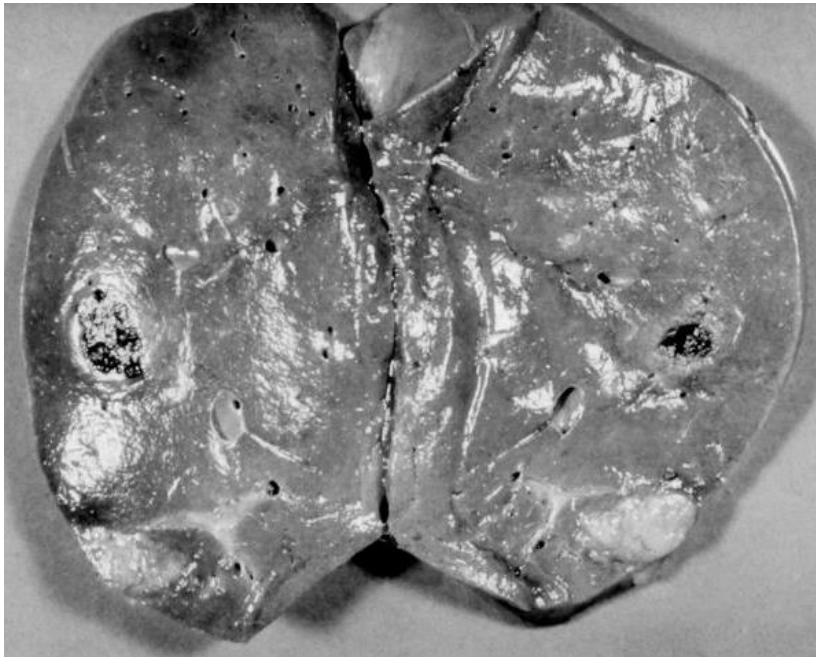


Further studies?

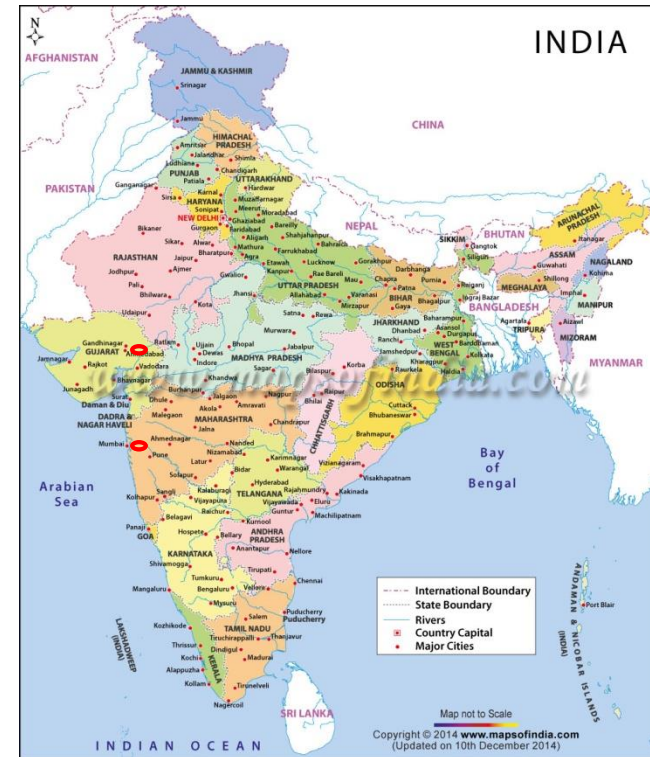Diagnosis?

- RPR: (+) at 1:8
- Diagnosis: Gummatous syphilis
- CSF exam: negative
- Benzathine penicillin 2.4 million units IM weekly x3 (J Infect Dis 1988,157:606)



Case 6 : 23-year-old man with fever after travel to India

- Previously well, returned from 3 week stay in Mumbai and Ahmedabad (via Dubai)
- 1 week later: 4-5 days of fever 103°F, headache, fatigue; no other symptoms
- Some relief from ibuprofen and amoxicillin-clavulanate



Immediate concerns?

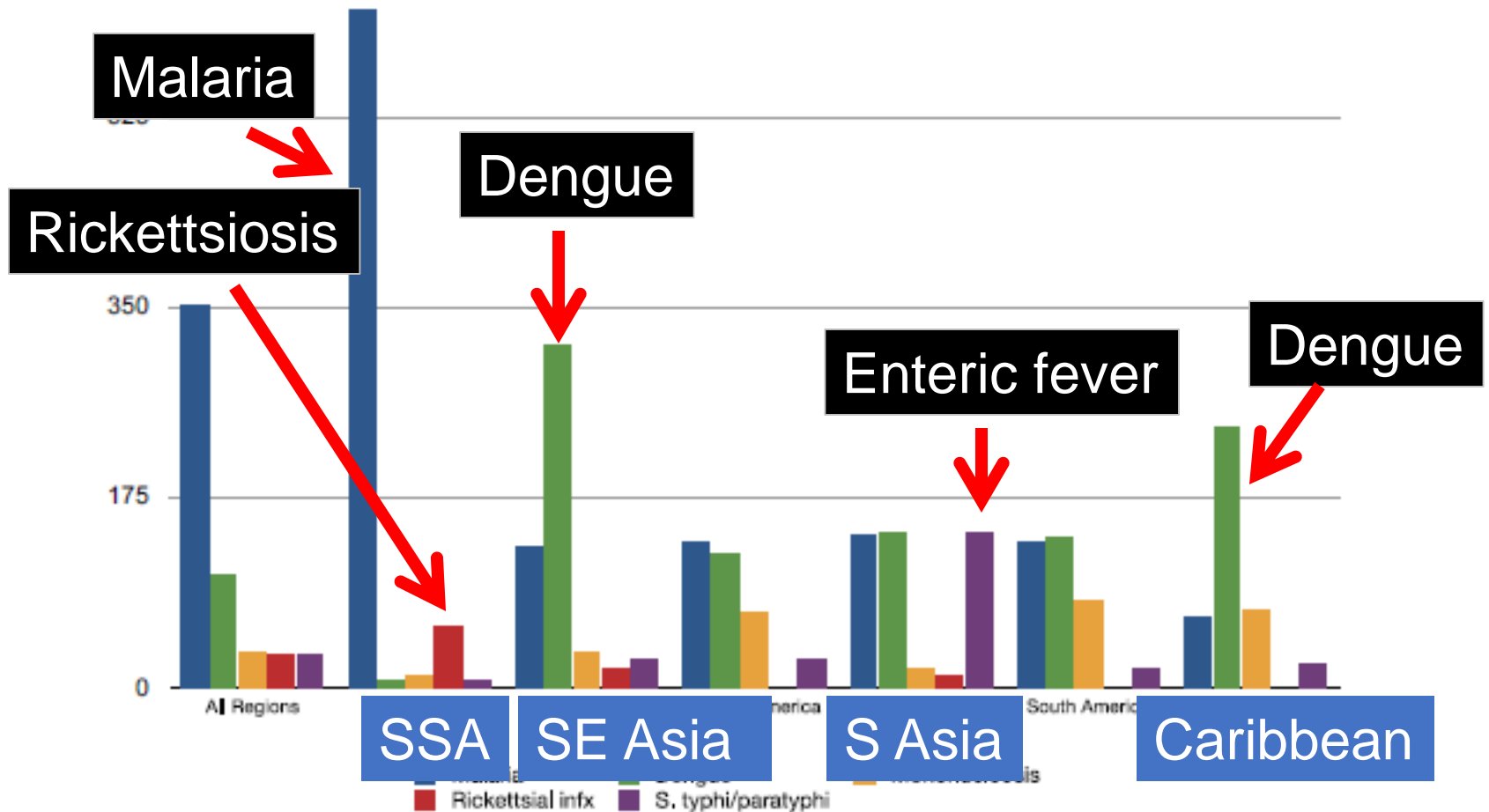
Immediate concerns

- Infections that may be rapidly fatal (malaria, typhoid, other bacterial septicemia, meningitis, rickettsial infections, hemorrhagic fevers)
- Infections that pose a public health threat and require institution of proper precautions (meningitis; hemorrhagic fevers; measles; MERS; COVID-19; hepatitis, tuberculosis)

Differential diagnosis?

Sytemic febrile illness. Number of cases per 1,000 diagnoses

700



N Engl J Med 2006; 354:119

- Visited family and friends, stayed mostly in the cities but did travel to countryside; not sick during travel
- Stayed in private homes
- Ate at homes, restaurants, street food; drank tap water
- Many mosquito bites; no animal contact, no freshwater exposure; no sexual contacts
- No one back home in India ill
- No vaccination for hepatitis A, typhoid, Japanese Encephalitis Virus; no malaria prophylaxis



Fatigued-appearing young man, no distress
Temp. 101.5° F., P.88/min, BP 110/70

Remainder of examination unremarkable.

WBC 6190 (51P,33L,15 Mo), Hct 40.3, plts 247,000
BUN 8, Creat 0.8, Alk phos 80, ALT 33, AST 35
Smear-negative for parasites; CXR-clear

Emergency room staff: discharge

Called back when blood culture returned positive

Diagnosis? Empirical treatment?

23-year-old man with fever after visiting family in India

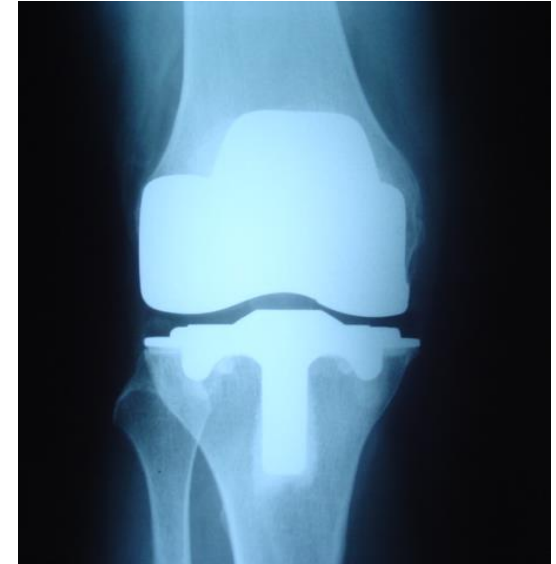- Blood cultures: gram-negative rods
- Ceftriaxone → hives
- Culture: *Salmonella typhi*
- ETEST: Ciprofloxacin 0.25 (Intermediate)
KB panel: Nalidixic acid 6.0 (Resistant)
- Treated with azithromycin, did well
- Nalidixic acid resistance=marker of decreased susceptibility to fluoroquinolones, highly prevalent in India (JAMA. 2009;302(8):859)
- Note: Highly resistant cases of typhoid primarily in Pakistan, but now seen among infections acquired in USA; CDC recommends empirical treatment with carbapenem or azithromycin (or both in severe cases)

Typhoid fever

- Risk in South Asia 6 to 30 times higher than East and Southeast Asia, Africa, the Caribbean, and Central and South America
- Oral live attenuated Ty21a vaccine: 1 capsule orally q48 hrs x4; boost every 5 years
- Vi capsular polysaccharide vaccine: intramuscular injection every 2 years
- Vi-TT typhoid conjugate vaccine (linked to tetanus toxoid; not yet available in US)
- Protection: 50-80%; not paratyphoid

Case 7: 60-year woman: swollen right knee, fever (102° F) x 1 day

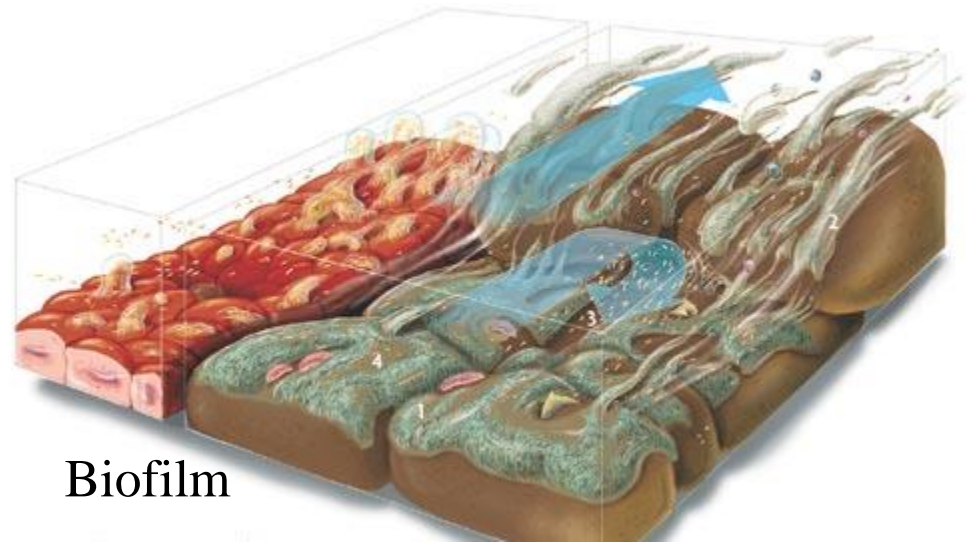
- Joint replaced 3 years earlier for osteoarthritis
- Synovial fluid WBC 110,000
- Gram-positive cocci in chains smear
- Culture: group G *Streptococcus*



Should the hardware be removed?

Foreign body infections

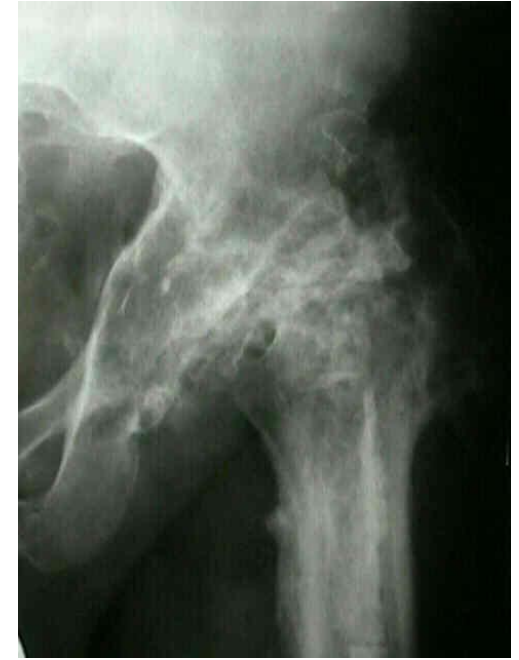- Conditioning of surface with fibronectin, fibrinogen, other host proteins
- Adherence of organisms to surface
- Production of biofilm (extracellular glycocalyx, “slime”)
- Metabolic changes: slow growth, decreased oxidative metabolism
- Insensitivity to certain antibiotics
- Impairment of host defenses in the vicinity of the foreign body (opsonization, phagocytosis, killing)



Treatment options: infected prosthetic joint

Antibiotics and:

- Delayed (2-stage) exchange
- Direct (1-stage) exchange
- Removal without replacement +/- arthrodesis
- Amputation
- Debridement with retention of prosthesis +/- suppressive antibiotic therapy



Girdlestone

Can infection be cured
without removal of hardware?

Outcome of prosthetic joint infections treated with debridement, iv antibiotics, retention of components, and (in 89%) chronic oral antibiotics for suppression

Table 4. Microbiologic findings of 99 episodes of prosthetic joint infection (PJI) occurring in 91 patients, 1995–1999.

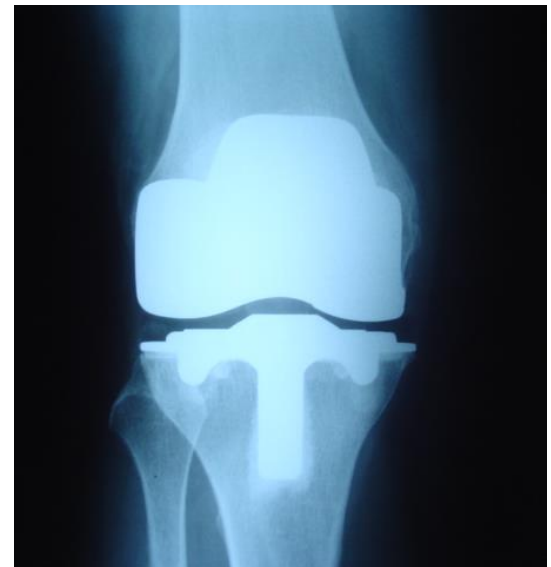Microorganism or infection	No. (%) of episodes	Proportion (%) of episodes treated successfully	Duration of follow-up for successfully treated episodes, median days (range)
Coagulase-negative staphylococci ^a	23 (23)	14/23 (61)	1135 (67–2146)
Culture-negative infection ^a	8 (8)	6/8 (75)	1655 (13–2410)
Fungi ^b	1 (1)	0/1 (0)	...
Other	2 (2)	1/2 (50)	139
Total	99 (100)	46/99 (46)	1194 (13–2779)

Overall, 46% of episodes treated successfully

- 79% of streptococcal infection
- only 13% of *Staph. aureus* infections
- rifampin not used

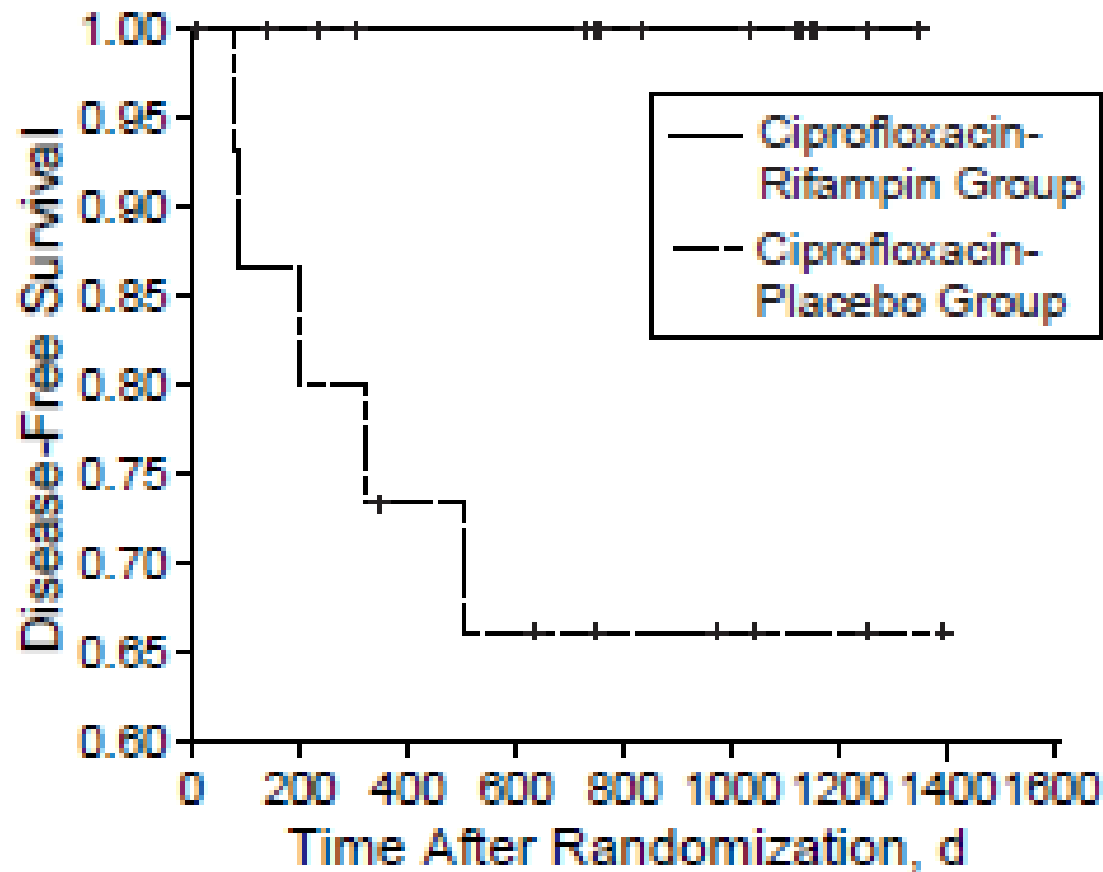
Case 7: 60-year woman: swollen right knee, fever (102° F) x 1 day

- Culture: group G *Streptococcus*
- Underwent debridement, washout and liner exchange; 6 weeks of IV ceftriaxone; 6 months of amoxicillin
- Infection free at 5 years



Ciprofloxacin/rifampin versus ciprofloxacin for 3-6 months following debridement and 2 weeks of iv antibiotics for treatment of staphylococcal infection of orthopedic devices (n=33)

Zimmerli W, JAMA 1998



Algorithm for the Treatment of Early or Hematogenous Infection Associated with a Prosthetic Joint

Criteria:

- Acute or hematogenous infection
- Duration of symptoms < 3 weeks
- Soft tissue: intact
- Organism susceptible to biofilm-acting antibiotic

Protocol:

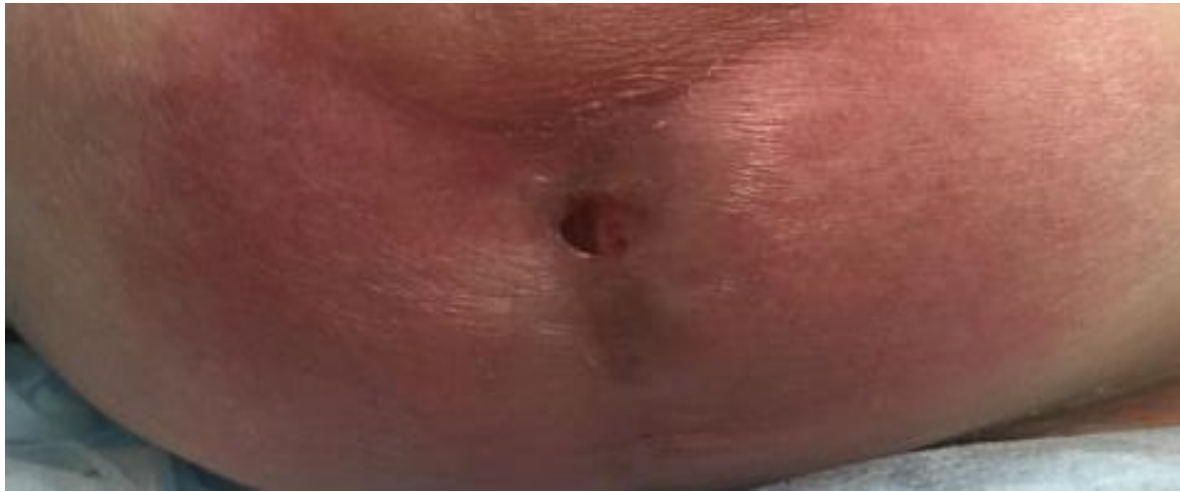
- Debridement
- IV antibiotics x 2-4 weeks
- Oral antibiotics (rifampin and quinolone, TMP-SMX, or doxycycline) x 3-6 months

Results:

- >80% *with S. aureus* relapse free at 3 years
- If all criteria not met, failure rate 32-86%

Case 8: 36-year-old woman with pain, swelling and purulent drainage after breast implants

- Previously healthy, traveled to Caribbean for plastic surgery
- Underwent bilateral silicone implant breast augmentation, liposuction, bilateral buttock fat injection
- 1 month later developed pain, redness, swelling and purulent drainage from the right breast
- No fever, sweats, chills; normal CBC



- Subsequently developed purulent drainage from left breast, abdominal wound, and both buttocks
- Underwent debridement and removal of implants; gram-stained smears and cultures were negative at three days

Most likely pathogen?

- A. MRSA
- B. Actinomyces
- C. Nocardia
- D. Mycobacterium
- E. Aspergillus

Most likely pathogen?

- A. MRSA
- B. Actinomyces
- C. Nocardia
- D. Mycobacterium
- E. Aspergillus

- *Mycobacterium abscessus* isolated in cultures 2 weeks later
- Sensitive only to amikacin, linezolid, clarithromycin; resistant to all other antibiotics tested including TMP-SMX, ceftazidime, moxifloxacin, imipenem, doxycycline, omadacycline, bedaquiline, clofazamine .
- Required removal of both implants and multiple surgical debridement of all sites
- Received 3 months of combination antibiotic therapy. No evidence of recurrence 3 years later.

- This was one of 12 cases with rapid-growing mycobacterial infection after cosmetic surgery in the Dominican Republic from the same clinic
- All isolates were identified as *Mycobacterium abscessus*, an organism ubiquitous in the environment (water, soil, dust)
- Treatment complicated by high rates of antimicrobial resistance; surgery usually required
- Well-described hazard of medical tourism

Case 9: 66-year-man with low back pain after working in the garden

- 8 weeks after onset:
 - Gradually worsening pain
 - No improvement with bed rest; worse at night
 - No fever, sweats, chills, anorexia
- PMH: TURP 4 months ago
- Examination: temperature 98.2°F, tenderness over lower lumbar spine, neurological examination unremarkable

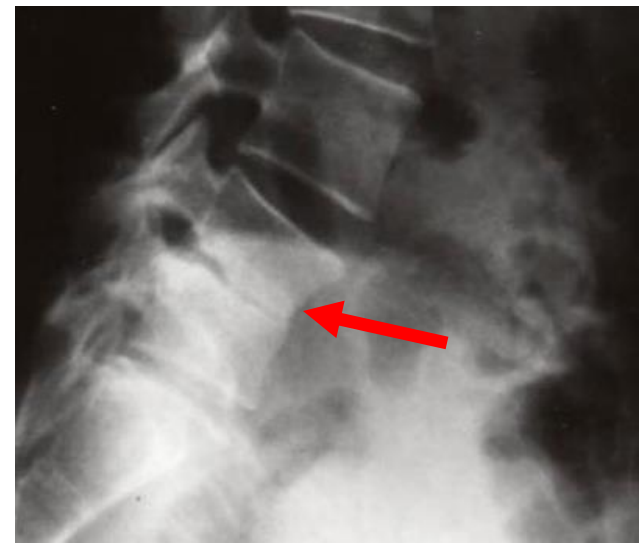
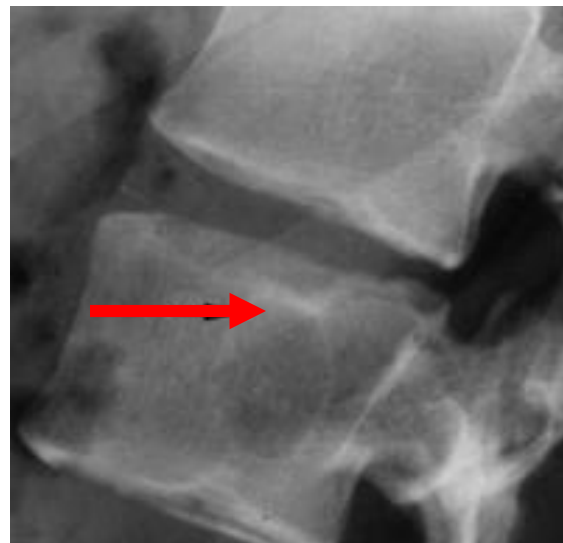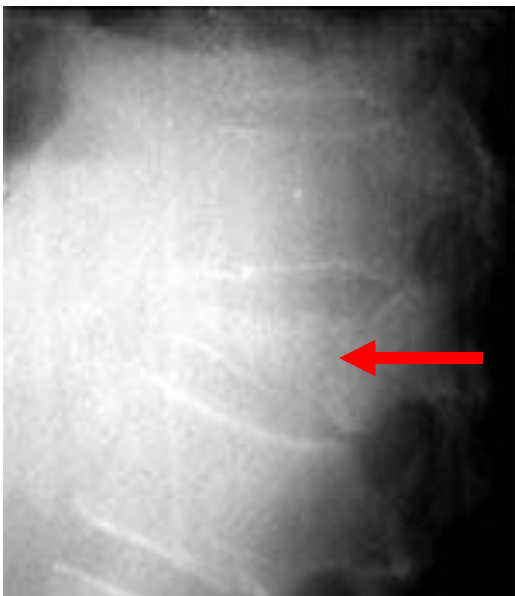- WBC 6000
- ESR 110
- Blood cultures and urine culture: (negative)

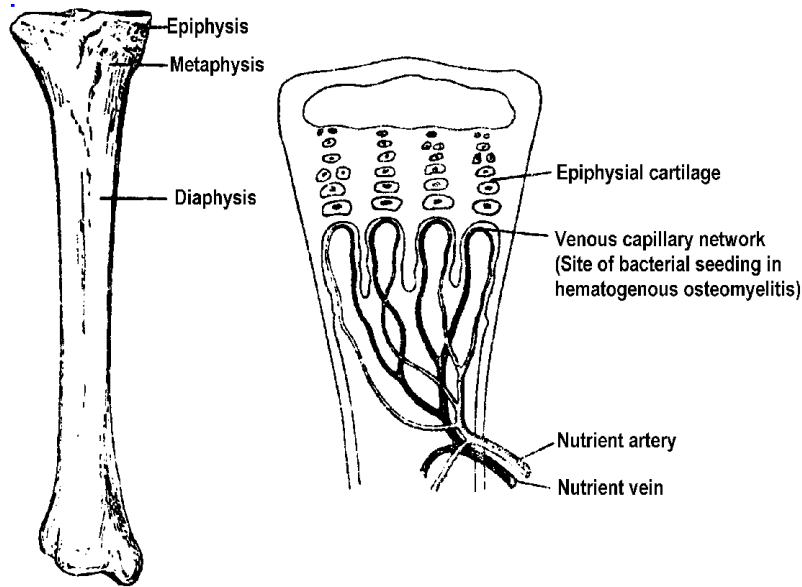
Could this be infection?

Spinal osteomyelitis

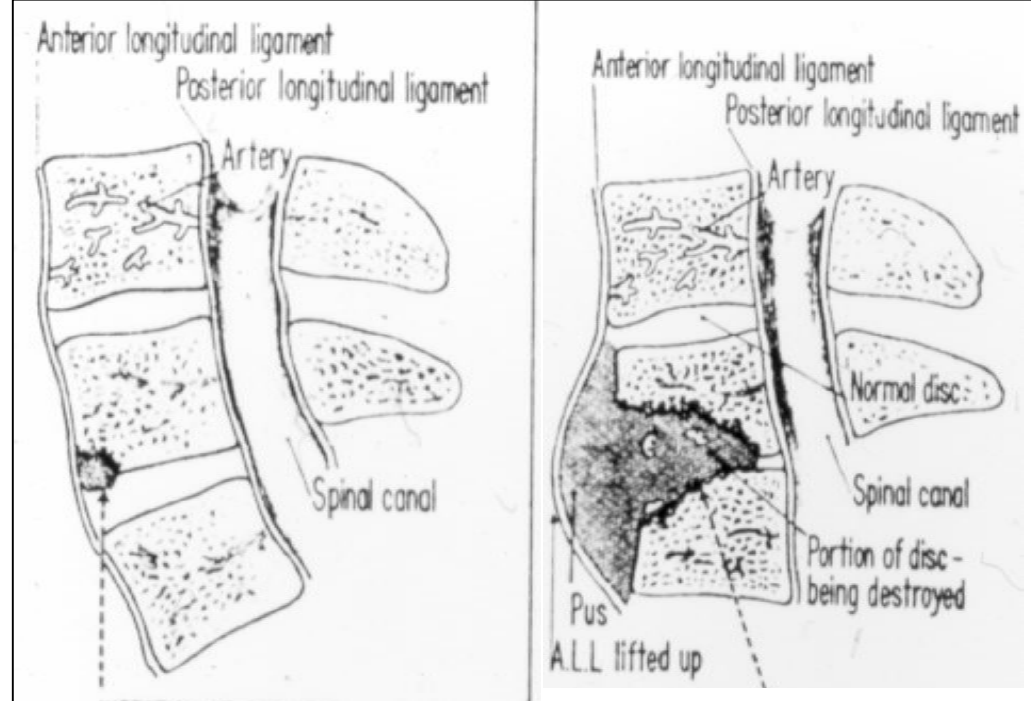
Neck or back pain	90%
Pain for > 3 months	50%
Atypical pain or symptoms (occipital, chest, abdominal, or extremity pain; dysphagia, pleural effusion, iliopsoas abscess)	15%
Neurological deficit	17%
Fever	50%
Leukocytosis	40%
Elevated ESR or CRP	>90%

Plain radiographs:
Which most consistent with diagnosis??





Long bone anatomy and vasculature



Hematogenous osteomyelitis

Childhood: long bones (metaphysis)

Adults>50 yrs: spine; (long bones rare; diaphysis)

IVDU: spine (53%)

sternoarticular (22%)

pelvic girdle (18%)

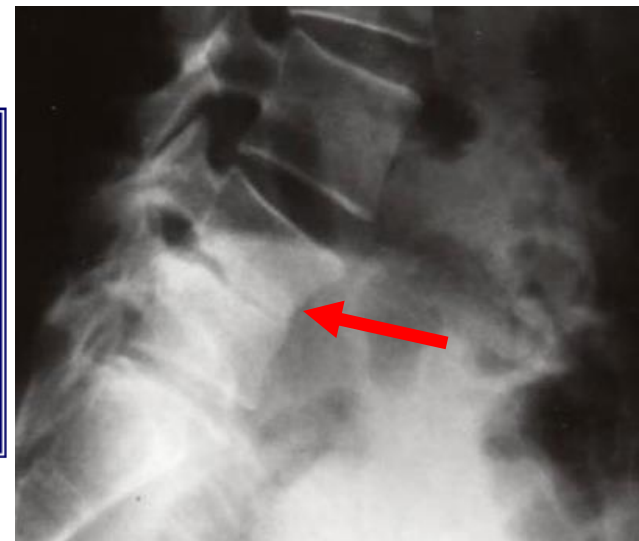
long bones (17%)

Scientific American Medicine 1985
Sapico 1980 Rev Infect Dis
Infect Immun 2020, 10.IAI, 00932

Plain radiographs:

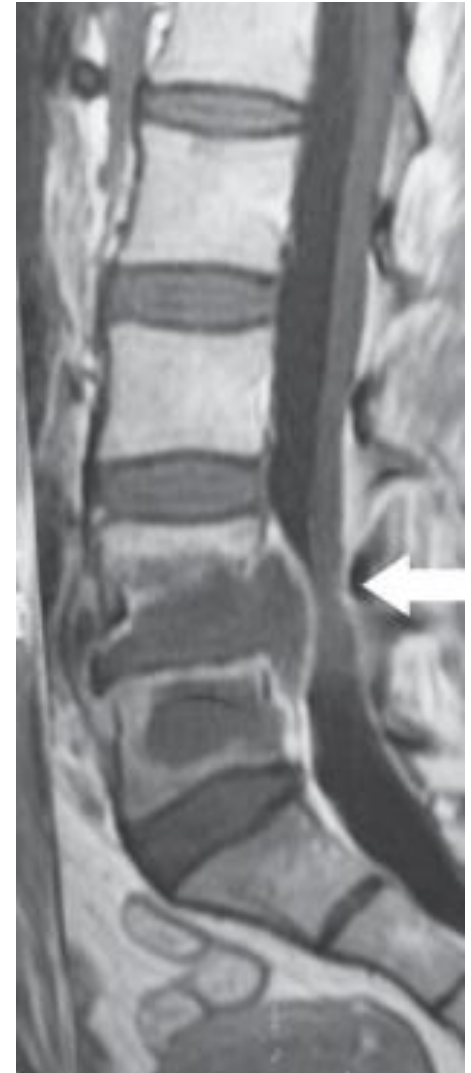Which most consistent with diagnosis??

Erosion of L4-5 end-plates
and narrowing of
intervening disc space



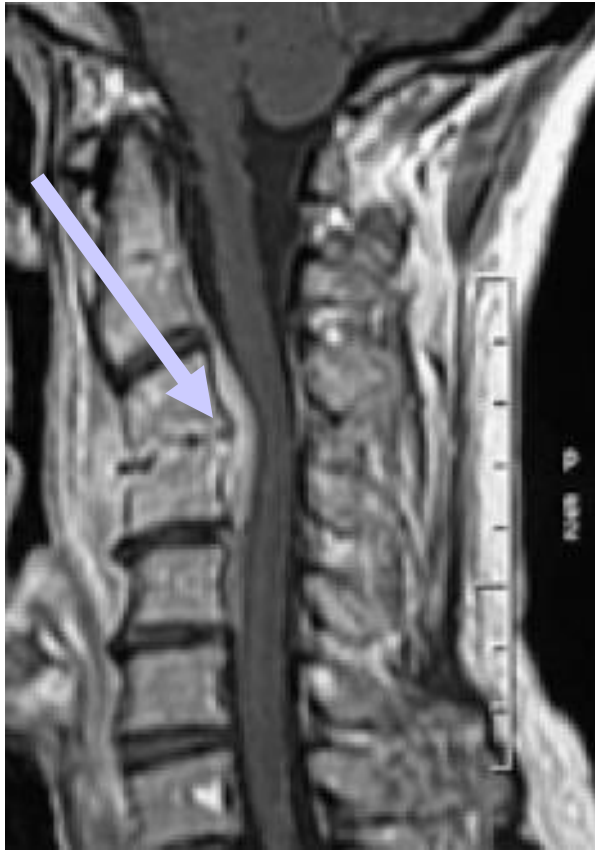MR: imaging modality of choice for suspected or confirmed spinal osteomyelitis

- Combined infection of the disc and vertebral bodies
- End-plate erosion
- Paravertebral or epidural inflammation/ or abscess



66-year old man with low back pain

- CT-guided needle aspirate x2: smears: few neutrophils; no organisms isolated
- Empirical vancomycin, ceftriaxone x 6 weeks
- Worsening pain at 3 weeks
 - ESR 130
 - Repeat MR: paraspinal abscess
- CT-guided needle aspirate: *E. coli* resistant to third generation cephalosporins
- Surgical debridement of abscess
- Ertapenem x 8 weeks
- 1 year later: pain free; ESR 26



Neurosurg Focus 2004

Spinal epidural abscess

- May occur in the absence of osteomyelitis
- Symptoms
 - Back or neck pain
 - Root pain
 - Weakness, sphincter dysfunction
 - Paralysis
- Need for urgent surgery depends on size and location
- Small collections esp. below cord may be treated medically

Case 10: 61-year-old woman with fever of unknown origin

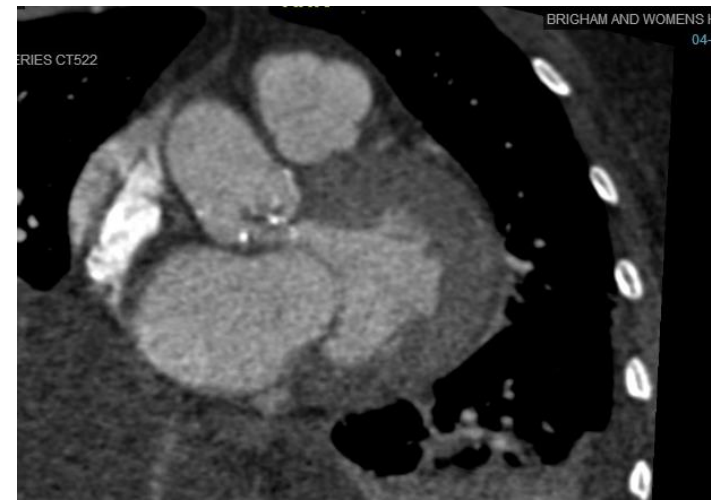
- Previously in good health with a history of gastric bypass surgery
- Gradual onset of fever and flulike symptoms
- Bilateral swelling/redness of lower legs; defervesced after doxycycline for presumed Lyme disease
- Over next 4 months, progressive fatigue, weakness, weight loss, low-grade fever
- Slight improvement with several courses of doxycycline and azithromycin

- Admitted to outside hospital with congestive heart failure
- Intermittent episodes of forgetfulness and confusion; spinal fluid remarkable for 9 WBCs with 66% neutrophils
- CT scans: cardiomegaly, small pleural effusions, mild splenomegaly
- Workup including multiple blood cultures, connective tissue serology: negative

- On examination at BWH, afebrile, fatigued-appearing but in no acute distress. Lungs: bibasilar rales, heart: 3/6 systolic ejection murmur at base. Abdomen: Obese, not tender. Extremities 2+ edema bilaterally. No rash.
- WBC 6190, 75% neutrophils, hematocrit 23.6, ESR 36, LFTs within normal limits; albumin 2.2, CRP 85. Multiple blood cultures negative.
- TTE: severe aortic stenosis, regurgitation

Now what?

- TEE not possible because of prior surgery
- Cardiac CT: 1.2 cm x 1.2 cm vegetation on aortic valve with perforation of left coronary cusp and severe aortic regurgitation
- Underwent aortic valve replacement and debridement of aortic root abscess
- Pathology: active endocarditis with gram-positive cocci
- Cultures: negative
- Molecular studies (CDC):
coagulase-negative
Staphylococcus



Culture negative endocarditis

- Previous administration of antibiotics
- Inadequate microbiological techniques
- Infection with highly fastidious bacteria or nonbacterial pathogens: *Brucella*, *Coxiella*, *Bartonella*, fungi, *Legionella*, *Tropheryma whippelii*, mycobacteria, *Abiotrophia*, others (HACEK organisms now usually isolated in culture); increasing role for molecular diagnostic techniques, such as 16s rRNA PCR/sequencing, metagenomic next-generation sequencing
- Noninfectious (nonbacterial thrombotic endocarditis)

Thank you!

jmaguire@bwh.harvard.edu